

Patient: **TEST, PATIENT**

Age: 68 (08/13/45)

Pathology #: **DPS-20-07442**

Acct#:

Sex: FEMALE

Doctor: Test, MD

Date Obtained: 05/15/2020

Date Received: 05/15/2020

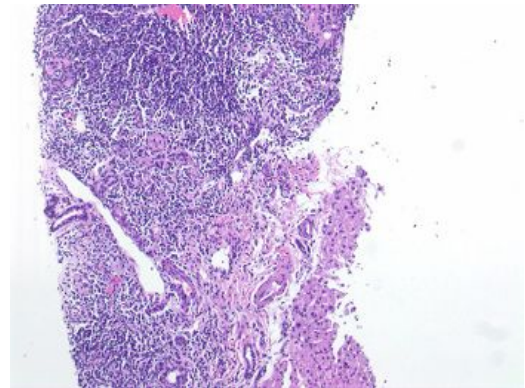
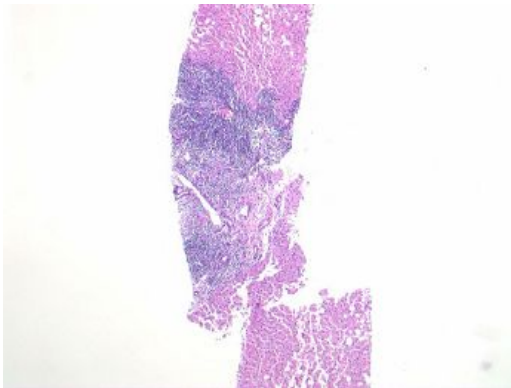
CLINICAL DATA: 573.9, ABNORMAL LFT'S

SPECIMEN: LIVER BIOPSY

DIAGNOSIS:

LIVER, BIOPSY:

- 1. CONSISTENT WITH PRIMARY BILIARY CIRRHOSIS, STAGE 1.**
- 2. PORTAL FIBROSIS (STAGE 1 OF 4).**



NOTE: Dr. Test's progress note (4/28/14) is reviewed. The patient has a clinical history of primary biliary cirrhosis. Reportedly, the patient had a positive antimitochondrial antibody. The patient's previous liver biopsy (DPS-10-4275) showed changes which favored primary biliary cirrhosis. At that time, it was a stage 1 lesion. The patient currently has an elevated alkaline phosphatase (184).

The biopsy shows three cores of liver tissue with approximately nineteen portal areas present for evaluation. Many of the portal areas show a mild chronic inflammatory infiltrate, consisting predominantly of lymphocytes. A few of the portal areas show a marked chronic inflammatory cell infiltrate. In these portal areas, florid duct lesions are present, characterized by the prominent inflammation, lymphocytic cholangitis, and bile duct epithelial damage/disruption of bile duct basement membrane. No granulomas are seen. Focally,



Patient: **TEST, PATIENT**

Age: 68 (08/13/45)

Pathology #: **DPS-20-07442**

Acct#:

Sex: FEMALE

Doctor: Test, MD

Date Obtained: 05/15/2020

Date Received: 05/15/2020

there is bile duct loss, but there is no ductopenia. There is focal interface hepatitis, but this is not a prominent histologic finding. There is no ductular reaction. No granulomas are seen. The lobules show mild macrovesicular steatosis (approximately 5%). There is no significant lobular inflammation present. The trichrome stain highlights portal fibrous expansion. The iron stain is negative for hemosiderin deposition. Overall, the histologic findings in this biopsy are consistent with the history of primary biliary cirrhosis, stage 1.

Staging and grading are done by using the Batts-Ludwig parameters (modified Knodell).

GROSS DESCRIPTION: EE:snc

Received in formalin in a container labeled with the patient's name and "liver R" are three cores of soft tissue measuring from 1.8 to 1.75 cm in length with an average diameter of 0.1 cm. They are entirely submitted between sponges in a single cassette. Iron and trichrome.

MB:sks; 573.9

This report may include a photomicrograph of the slide under examination. For a variety of reasons, including the limitations of some electronic interfaces, the photomicrograph may not appear on the version of this report that you view. The photomicrograph is not of diagnostic quality and should not be relied upon by any professional. Health care professionals should rely only upon the pathologist's written interpretation.

Final Diagnosis performed by **Marian Butcher, M.D.**

Electronically signed 05/16/2020

Sutter General Hospital,
2801 L Street SACRAMENTO, CA 95816