

Patient: **TEST, PATIENT**

Age: 54 (05/15/60)

Pathology #: **DPS-23-12794**

Acct#:

Sex: MALE

Doctor: Test, MD

Date Obtained: 08/13/2023

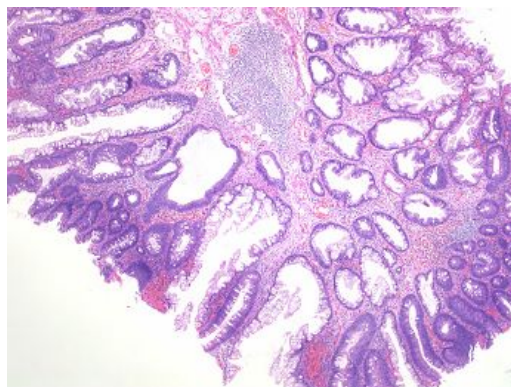
Date Received: 08/14/2023

CLINICAL DATA: COLONOSCOPY WITH POLYPECTOMY, A: VERY SMALL POLYP QUESTIONABLE RETRIEVAL, B: POLYPECTOMY, C: NONE PROVIDED

SPECIMEN:
A. CECAL POLYP HOT SNARE
B. @ 30 CM SIGMOID (POLYP PER BOTTLE) HOT SNARE
C. @ 25 CM SIGMOID POLYP SNARE

DIAGNOSIS:

- A. COLON, CECAL POLYP, SNARE: TUBULAR ADENOMA.**
- B. COLON, SIGMOID POLYP AT 30 CM, SNARE:**
 - 1. TUBULOVILLOUS ADENOMA.**
 - 2. THE POLYP STALK MARGIN APPEARS NEGATIVE FOR ADENOMATOUS EPITHELIUM (ENDOSCOPIC CORRELATION RECOMMENDED).**
- C. COLON, SIGMOID POLYP AT 25 CM, SNARE: SESSILE SERRATED ADENOMA WITH LOW-GRADE DYSPLASIA.**



C



Patient: **TEST, PATIENT** Age: 54 (05/15/60) Pathology #: **DPS-23-12794**
Acct#: Sex: MALE
Doctor: Test, MD Date Obtained: 08/13/2023
Date Received: 08/14/2023

NOTE: C. Multiple levels were examined. The polyp is a sessile serrated adenoma with low grade dysplasia.

Colonic mucosal sessile serrated adenomas (sessile serrated polyps) have a unique histologic appearance. The importance of this diagnosis is that there is an increased association of this type of polyp with microsatellite instability (MSI) adenocarcinoma of the colon. These polyps, often sessile grossly, should be completely removed. If there is adjacent frank adenomatous change in the polyp, a more aggressive approach might be warranted including reducing the colonoscopic surveillance interval.

GROSS DESCRIPTION: MS:kg

- A. Received in formalin in a container labeled with the patient's name and "cecal polyp (snare)" is a single tan soft tissue fragment measuring 0.2 x 0.1 x 0.1 cm. The specimen is entirely submitted between sponges in cassette A.
- B. Received in formalin in a container labeled with the patient's name and "sigmoid polyp @ 30 cm (snare)" are two tan soft tissue fragments measuring 1.2 x 0.8 x 0.55 cm and 0.9 x 0.6 x 0.5 cm. The largest piece is inked black, trisected and entirely submitted between sponges in cassette B1. The second piece is inked black, trisected and entirely submitted between sponges in cassette B2.
- C. Received in formalin in a container labeled with the patient's name and "@ 25 cm, sigmoid polyp snare" are three tan soft tissue fragments measuring from 0.7 x 0.4 x 0.3 cm to 0.4 x 0.2 x 0.15 cm. The second largest piece is bisected. The specimens are entirely submitted between sponges in cassette C.

MB:snc; 211.3

This report may include a photomicrograph of the slide under examination. For a variety of reasons, including the limitations of some electronic interfaces, the photomicrograph may not appear on the version of this report that you view. The photomicrograph is not of diagnostic quality and should not be relied upon by any professional. Health care professionals should rely only upon the pathologist's written interpretation.

Final Diagnosis performed by **Marian Butcher, M.D.**

Electronically signed 08/15/2023
Sutter General Hospital,
2801 L Street SACRAMENTO, CA 95816