

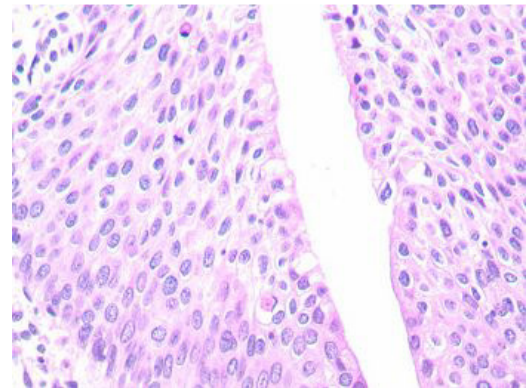
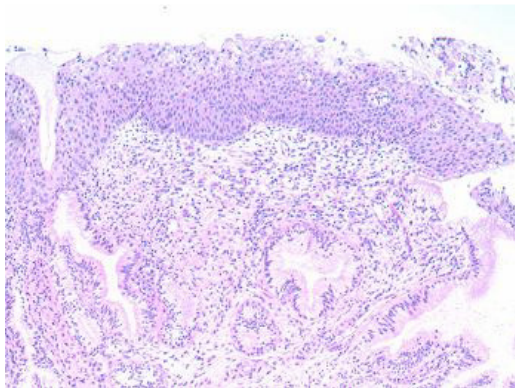
Patient: **PATIENT, TEST** Age: 25 (01/01/88) Pathology #: **DPS-14-99999**
Acct#: Sex: FEMALE Epic: 1419329
Doctor: TEST DOCTOR M.D. Date Obtained: 03/05/2014
Date Received: 03/06/2014

CLINICAL DATA: 795.02

SPECIMEN: A. CERVIX @ 6:00 BX
B. CERVIX @ 8:00 BX
C. ECC

DIAGNOSIS:

- A. **CERVIX, BIOPSY AT 6:00: ACTIVE CHRONIC CERVICITIS WITH REACTIVE EPITHELIAL CHANGES.**
- B. **CERVIX, BIOPSY AT 8:00: SEVERE SQUAMOUS DYSPLASIA (CIN 3).**
- C. **ENDOCERVIX, CURETTINGS: MUCUS AND SCANT INFLAMED ENDOCERVICAL MUCOSA WITHOUT DIAGNOSTIC FEATURES OF DYSPLASIA.**



NOTE: The patient is status post review of cervical cytology in February 2014 that showed atypical squamous cells, cannot exclude HGSIL (ASC-H). The previous cervical cytology, TPC-14-9998, is concurrently reviewed.

