

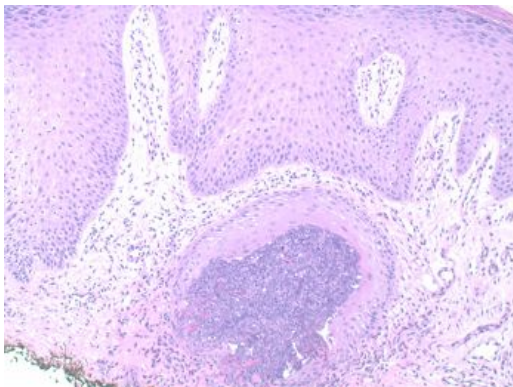
Patient: TEST, PATIENT Age: 14 (01/01/00) Pathology #: DDS-14-10962  
Acct#: Sex: MALE DPMG use only: 0730&0230/#11/P  
Doctor: DPMG Date Obtained: 04/30/2014  
3301 C st Suite 200E Date Received: 05/01/2014  
Sacramento CA, 95816

**CLINICAL DATA:** 238.2, A: R/O WART, B: R/O TINEA

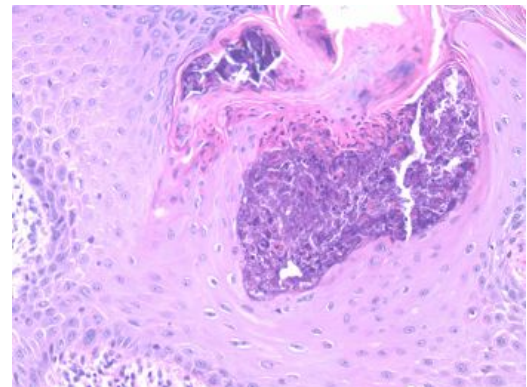
**SPECIMEN:** A. RIGHT ARM SHAVE BIOPSY  
B. LEFT NECK SHAVE BIOPSY

**DIAGNOSIS:**

- A. SKIN, RIGHT ARM, SHAVE BIOPSY:  
COMPATIBLE WITH PERFORATING DISORDER WITH FEATURES OF  
ELASTOSIS PERFORANS SERPIGINOSA.**
- B. SKIN, LEFT NECK, SHAVE BIOPSY:**
- 1. COMPATIBLE WITH PERFORATING DISORDER WITH FEATURES OF ELASTOSIS PERFORANS SERPIGINOSA.**
  - 2. ASSOCIATED SPONGIOTIC DERMATITIS WITH OCCASIONAL EOSINOPHILS (SEE NOTE).**




**A**



**B**

**NOTE:** Elastosis perforans serpiginosa presents as small papules, either grouped or in a circular or serpiginous arrangement, often on the face, neck, upper extremities, and trunk. The disorder has a predilection for males and typically occurs in the second decade. Up to a third of cases have been reported to be associated with an associated systemic disorder or connective tissue disorder. Some cases are associated with prolonged use of penicillamine. Clinical correlation is recommended.



Patient: **TEST, PATIENT** Age: 14 (01/01/00) Pathology #: **DDS-14-10962**  
Acct#: Sex: MALE DPMG use only: 0730&0230/#11/P  
Doctor: DPMG Date Obtained: 04/30/2014  
3301 C st Suite 200E Date Received: 05/01/2014  
Sacramento CA, 95816

**GROSS DESCRIPTION: TMA:kg**

- A. Received in formalin in a container labeled with the patient's name and "R arm" is a single 0.5 x 0.4 x 0.1 cm irregular light grey-tan rough portion of tissue. The specimen is inked, bisected, wrapped in biopsy paper and submitted entirely in cassette A.
- B. Received in formalin in a container labeled with the patient's name and "L neck" is a single 0.5 x 0.4 x 0.1 cm irregular tan smooth portion of tissue. The specimen is inked, bisected, wrapped in biopsy paper and submitted entirely in cassette B.

**MICROSCOPIC DESCRIPTION:**

The sections show a hyperplastic epidermis with channels containing brightly eosinophilic elastic fibers and basophilic debris. The adjacent dermis contains foci of foreign-body giant cells. Special stains for micro-organisms (PAS and GMS on both parts A and B, Gram on part A) are negative.

DKM:kg; 709.8

This report may include a photomicrograph of the slide under examination. For a variety of reasons, including the limitations of some electronic interfaces, the photomicrograph may not appear on the version of this report that you view. The photomicrograph is not of diagnostic quality and should not be relied upon by any professional. Health care professionals should rely only upon the pathologist's written interpretation.

Final Diagnosis performed by **Derek K Marsee M.D., Ph.D**

Electronically signed 05/07/2014

Diagnostic Pathology Medical Group,  
3301 C Street, Suite 200E SACRAMENTO, CA 95816